

Research Article

# Early Surgical Management of Appendicular Mass: Evaluation of Surgical Outcome in Selected Private and Government Hospitals, Bangladesh

Jahangir Md Sarwar, Abul Kalam Md Shamsuddin, Sirajam Munira\* 

Sheikh Russel National Gastroliver Institute and Hospital, Dhaka, Bangladesh

## Abstract

**Background:** Appendicular mass, a common occurrence in acute appendicitis (10% of cases), develops within 24-48 hours of symptom onset. Management strategies, including early appendectomy, non-operative management with or without drainage, and interval appendectomy, vary widely. This study aims to evaluate the outcomes of early surgical management and compare different surgical approaches. **Methodology:** This retrospective observational study was performed in different private and government hospital at Jamalpur, Manikgonj for a period of 8 years from January 2015 to December 2022. A total of 288 consecutive patients meeting eligibility criteria underwent open appendectomy within 24 hours of hospital admission due to appendicular lump diagnosis based on clinical or ultrasonographic findings. Two surgical techniques were employed: appendicectomy with generalized peritoneal toileting and appendicectomy with loco-regional peritoneal toileting. All data were collected from hospital records. Follow-up records for a period of 2 weeks and at the end of 1 year were reviewed. **Results:** Patients had a mean age of 30.04 years, mostly male and under 30 years old. Appendicular lump with abscess was predominant (73.96%), along with perforated appendix and presence of pus (71.18% and 75.35% respectively). 68.75% underwent appendicectomy with loco-regional toileting, and 31.25% with generalized peritoneal toileting. Both groups were similar in demographics and perioperative findings, with common difficulties in localization and dissection (76.79% and 88.89% respectively). No bowel injuries occurred in the loco-regional toileting group. Postoperative complications were significantly lower in this group, especially superficial and deep wound infections (11.61% vs 16.67%, 2.53% vs 10%). Fecal fistula and incisional hernia were observed in the generalized peritoneal toileting group (1.11%, 2.22%). Operative time was notably shorter in the loco-regional peritoneal toileting group (92 minutes vs 65 minutes). **Conclusion:** Early appendicectomy allows for single-admission treatment, serving as an effective alternative to conservative therapy by significantly reducing hospital stays and expenses. Specifically, early appendicectomy with loco-regional peritoneal toileting demonstrates shorter operative times and lower post-operative complications compared to generalized peritoneal toileting, suggesting its favorable utility in managing appendicular mass and warranting further optimization in surgical strategies.

## Keywords

Early Surgery, Appendicular Mass, Loco-regional Peritoneal Toileting, Generalized Peritoneal Toileting, Bangladesh

\*Corresponding author: [muniradmck65@gmail.com](mailto:muniradmck65@gmail.com) (Sirajam Munira)

**Received:** 16 May 2024; **Accepted:** 31 May 2024; **Published:** 19 June 2024



Copyright: © The Author (s), 2024. Published by Science Publishing Group. This is an **Open Access** article, distributed under the terms of the Creative Commons Attribution 4.0 License (<http://creativecommons.org/licenses/by/4.0/>), which permits unrestricted use, distribution and reproduction in any medium, provided the original work is properly cited.

## 1. Introduction

Acute appendicitis, a prevalent acute abdominal condition in surgical practice, often manifests as an appendicular mass, constituting up to 10% of cases [1-3]. This condition, ranging from phlegmon to abscess formation, develops within 24 to 48 hours of symptom onset, comprising the inflamed appendix, omentum, and bowel loops as a protective mechanism against infection spread [4-6]. Despite its frequent occurrence, the management of appendicular mass remains controversial over decades. It constitutes a significant portion of acute surgical abdomen cases in children, with 10% of acute appendicitis cases presenting as appendicular mass, and a notable percentage involving perforation [7]. Treatment strategies vary widely, with approaches encompassing early appendectomy, non-operative management with or without percutaneous drainage, and interval appendectomy. Conservative management with interval appendectomy, advocated since the early 1900s, remains widely practiced, while the emerging trend towards omitting interval appendectomy challenges established norms due to low infection and recurrence rates. There are contradicting evidences to prove superiority of one over another. With conservative treatment being the favored option, the debate over the necessity of interval appendectomy persists, driven by considerations of recurrence risk and post-treatment outcomes [8, 9].

Traditionally, conservative management followed by interval appendectomy 4 to 6 weeks later has been the standard approach for patients with appendicular mass. This strategy aims to mitigate the perceived risks associated with early appendectomy, including potential complications such as fecal fistula, which are considered hazardous and time-consuming. However, proponents of immediate appendectomy argue for a definitive operative intervention during the initial admission. Studies supporting immediate appendectomy suggest advantages such as expedited recovery and complete resolution within the same admission, thus reducing the need for subsequent readmission for interval appendectomy and promptly excluding other pathologies [10-13]. Therefore, our study aims to observe the outcome of early surgical management of appendicular mass and to compare between different surgical approaches practiced.

## 2. Methodology

In this retrospective Cross sectional study, we reviewed the cases of 288 patients with appendicular mass who underwent early appendectomy within an 8-year period from January 2015 to December 2022 at the Department of General Surgery, Manikgonj Sadar Hospital, Manikgonj, Dhaka. Early appendectomy was defined as the surgical removal of the appendix within 24 hours of admission and within 14 days of the onset of an acute appendicitis attack. Diagnosis of appendicular mass was established clinically, through ultrasonography, or during surgical exploration. Patients with a lump in the right iliac fossa

due to worm bolus, ileo-caecal tuberculosis, or carcinoid tumor were excluded from the study. Additionally, patients with contraindications to surgery or incomplete medical records were also excluded. All patients underwent laparotomy, with the operative approach being a lower right paramedian incision. Two types of operative procedures were performed: laparotomy followed by appendectomy with generalized peritoneal toileting in 90 patients, and laparotomy followed by appendectomy with local peritoneal toileting in 198 patients. Data collection involved reviewing medical records for demographic information, indications for surgery, surgical procedures performed, and postoperative outcomes. Surgical outcomes, including postoperative complications, length of hospital stay, and postoperative pain assessment, were evaluated as dependent variables. Follow-up records for a period of 2 weeks were reviewed, and patients were also assessed for late complications such as incisional hernia at 1 year. Statistical analysis included descriptive statistics to summarize patient characteristics, and inferential statistics were used to compare outcomes between the two surgical approaches performed. Categorical variables were described in terms of frequency and percentage, while continuous variables were expressed as mean  $\pm$  standard deviation or median. Student's t-test and the chi-squared test were conducted using STATA version 17, with the level of significance set at 5% ( $P < 0.05$ ).

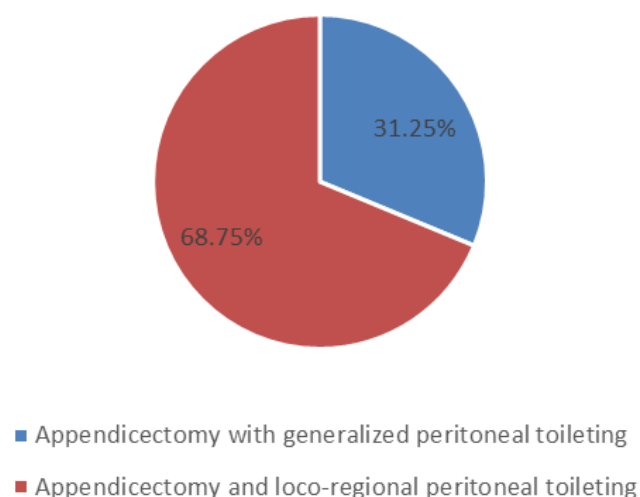
**Table 1.** Baseline characteristics of patients.

Variables	Frequency (n=288)	Percentage
Age category		
0-10	19	6.60
11-20	64	22.22
21-30	97	33.68
31-40	53	18.40
41-50	53	11.46
>50	22	7.64
Gender		
Male	160	55.56
Female	128	44.44
Mean age: 30.04 $\pm$ 14.34 SD		

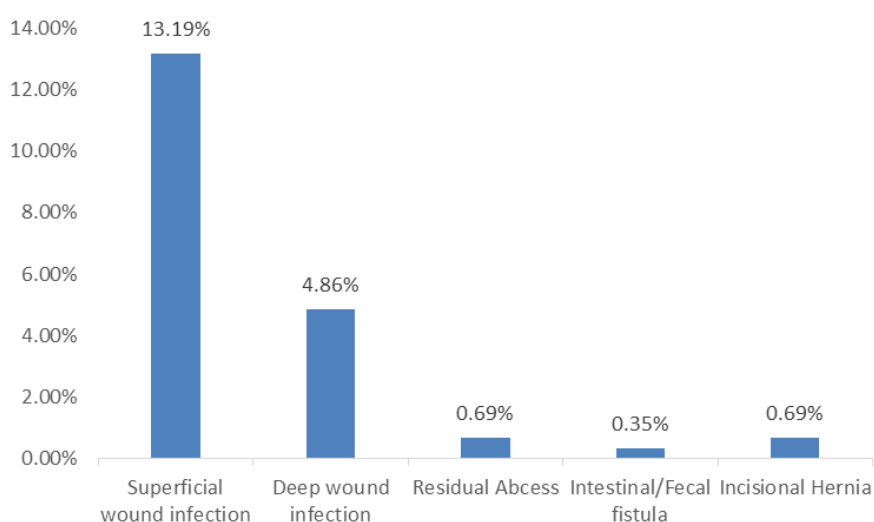
**Table 2.** Per operative findings of patients.

Diagnosis	Frequency	Percentage
Appendicular lump	69	23.96

Diagnosis	Frequency	Percentage
Appendicular abcess	03	1.04
Appendicular lump with abcess	213	73.96
Appendicular lump with abcess with left ovarian cyst	1	0.35
Appendicular lump with purulent peritonitis	1	0.35
Appendicular lump with sloughing of Caecum	1	0.35
Per operative Appendix condition		
Perforated	205	71.18
Phlegmonous	156	54.17
Gangrenous	08	2.78
Presence of pus	217	75.35



**Figure 1.** Patient distribution by operative technique.



**Figure 2.** Distribution of post-operative complications among patients.

**Table 3.** Operative findings of two groups.

Variables	Appendicectomy and generalized peritoneal toileting (n=90) N (%)	Appendicectomy with loco-regional peritoneal toileting (n=198) N (%)	P-value
Mean age $\pm$ SD	29.04 $\pm$ 10.12	31.23 $\pm$ 9.15	0.64
Operative findings			
Simple mass	21 (23.33%)	59 (29.80)	.049
Pus collection	60 (66.67%)	120 (60.68)	
Appendicular abcess	09 (10%)	19 (9.60)	
Operative Complication			
Difficulty in localization of appendix	83 (92.22%)	189 (95.45)	
Difficulty in dissection	69 (76.67%)	176 (88.89)	

Variables	Appendicectomy and generalized peritoneal toileting (n=90) N (%)	Appendicectomy with loco-regional peritoneal toileting (n=198) N (%)	P-value
Bleeding	5 (5.56%)	27 (13.64)	.071
Adjacent bowel injury	01 (1.11%)	00 (0.00)	
Need to extend incision	8 (8.89%)	13 (6.57)	
Mean Operative time (minutes)	92	65	.023

**Table 4.** Distribution of post-operative complication between two groups.

Post-operative complication	Appendicectomy and generalized peritoneal toileting (n=90) N (%)	Appendicectomy with loco-regional peritoneal toileting (n=198) N (%)	P-value
Superficial wound infection	15 (16.67)	23 (11.61)	
Deep wound infection	09 (10)	05 (2.53)	
Residual Abscess	00 (00)	02 (1.01)	.038
Intestinal/Fecal fistula	01 (1.11)	00 (00)	
Incisional Hernia	02 (2.22)	00 (00)	

### 3. Results

Among 288 patients with appendicular lump, nearly two-third patients (61.3%) admitted with appendicular lump were below 30 years of age and only 7.6% were above 50 years of age. Children below 10 and elderly frequency of lump formation was less. The mean age of patient was 30.04 years with male predominance.

Among all the patient with abdominal lump, per operative; the most common diagnosis is appendicular lump with abscess, accounting for 73.96% of cases. One patient had appendicular lump with sloughing out of caecum and another one patient with appendicular lump and purulent peritonitis. Perforated appendices and presence of pus were the most prevalent, representing 71.18% and 75.35% of cases respectively. Only 2.78% had gangrenous appendix.

Post-operatively, superficial wound infection developed in 13.19% patients whereas only 4.86% had deep wound infection. Only one patient experienced fecal fistula and unfortunately this patient had per-operative sloughed out caecum. Incisional hernia was reported in one patient during 1 year follow up.

During operation, we followed two techniques, 68.75%(198 cases) underwent appendicectomy with loco-regional peritoneal toileting and 31.25% patients (90 cases) underwent appendicectomy with generalized peritoneal toileting. In the first two years of the study period, appendicectomy with generalized peritoneal toileting was performed in nearly all patients and later on loco-regional peritoneal toi-

leting was preferred by the surgeon.

Based on the appendicectomy technique. Mean age was slightly higher in loco regional toileting group (31.04 vs 29.23 year) although the association was not statistically significant. Localization of appendix and surgical dissection was difficult in majority of the cases in both techniques (76.69-88.89%). No adjacent bowel injury happened in loco-regional toileting group whereas one patient had bowel injury in generalized peritoneal toileting group. Mean operation time was significantly lower in loco-regional toileting group (92 minutes' vs 65 minutes).

Comparing the post- operative complication between two groups, overall complication rate was hoigher in patients undergoing appendicectomy with generalized peritoneal toileting Superficial wound infection and deep wound infection rate were lower in loco-regional toileting group [1]. Residual abcess developed in 2 patients in loco-regional toileting group but no fecal fistula or intestinal hernia recorded in this group.

### 4. Discussion

Appendiceal mass formation typically arises from appendiceal wall perforation [14]. Three management approaches exist: emergency surgery, conservative management followed by interval surgery, and entirely conservative management without interval surgery [15]. This study emphasizes early surgery to reduce repeat consultations and hospital admissions, alleviate patient suffering, and promote early recovery.

Among 288 patients, the majority of patients (33.68%) fall within the age range of 21-30 years, with male predominancel.

The mean age of the patients is 30.04 years, with a standard deviation of 14.34 years. similar observations were encountered by study carried by Patel BJ [16] and Gilker I A et al [9]. But Rahman, M. A. M., Chowdhury found that majority of the patients were below 12 years of age [17], this may be due to the fact that the study hospital was paediatrics based hospital, therefore less adult attendance.

The most common diagnosis in the index study was appendicular lump with abscess, accounting for 73.96% of cases. Perforated appendices are the most prevalent, representing 71.18% of cases. Appendicular lump with presence of pus was also the predominant findings by Rahman, M. A. M., Chowdhury et al [17]. MA. Bahram also found All patients had a fixed appendicular mass with peri-appendiceal abscesses and adhesions which strongly supports our study [18].

During the operation, two techniques were employed: 68.75% (198 cases) underwent appendectomy with loco-regional peritoneal toileting, while 31.25% (90 cases) underwent appendectomy with generalized peritoneal toileting. Initially, during the first two years of the study, almost all patients underwent appendectomy with generalized peritoneal toileting, but later in the study period, the surgeon preferred loco-regional peritoneal toileting. All 288 operations were performed by the principal author of this study by himself. The loco-regional toileting during appendectomy was a new techniques employed by the surgeon based on her operative experience as this technique involves less operative time, less handling and lower post-operative complications. All these were the observation of surgeon himself; therefore, further study involving this method is required to establish its benefits over the widely practiced generalized peritoneal toileting method.

The index study compares the operative findings of two groups based on the type of appendectomy performed. There is no significant difference in mean age between patients undergoing different surgical approaches. However, there is a significant difference in the frequency of pus collection, with a higher incidence observed in patients undergoing appendectomy with generalized peritoneal toileting. Although not statistically significant, there is a trend towards higher rates of bleeding in patients undergoing appendectomy with loco-regional peritoneal toileting. Additionally, patients undergoing appendectomy with generalized peritoneal toileting had a significantly longer mean operative time compared to those with loco-regional peritoneal toileting.

Gilkar IA also recorded the above mentioned complication after early surgery but the complication rates were than loco-regional toileting group and comparable with generalized peritoneal toileting group which supports the superiority of loco-regional toileting [19]. E. S. Garba's observations, the emergency group experienced higher rates of both operative and post-operative complications compared to the other group, where they noted a complication rate of approximately 36%, comparable to that of perforated appendicitis. Immediate surgery increases the risk of infection dissemination and in-

testinal fistula formation, potentially negating the anticipated benefits [20, 21] but in our study the complication rates were comparably lower and no fecal fistulae or incisional hernia recorded.

This study showed the distribution of postoperative complications between the two groups. The incidence of superficial wound infection and deep wound infection was slightly higher in patients undergoing appendectomy with generalized peritoneal toileting, although not statistically significant. However, there is a significant difference in the incidence of residual abscess between the two groups, with a higher rate observed in patients undergoing appendectomy with loco-regional peritoneal toileting. Additionally, two cases of incisional hernia were reported in patients who underwent appendectomy with generalized peritoneal toileting. Ali et al. found emergency appendectomy to be a safe, cost-effective alternative to conservative management for appendicular mass. Khan et al. conducted trials on 300 patients, with immediate appendectomy showing lower wound infection rates (5% vs. 8%) and less than 2% intra-abdominal abscess frequency. Arshad et al.'s comparative study on 176 patients favored immediate appendectomy despite higher infection rates, citing shorter hospital stays [22-24]. All these study findings support the index study.

Considering the operative duration and post-operative complications, the loco-regional peritoneal toileting group shows favourable outcomes than the traditional generalized peritoneal toileting group. This suggests that the surgeons can adopt this technique for better operative outcome and patients benefits.

Strengths of this study include its large sample size, comprehensive data collection spanning an 8-year period, and focus on early appendectomy for appendicular mass. Additionally, the inclusion of both perioperative and postoperative outcomes enhances the robustness of the findings. However, limitations include its retrospective design, which may introduce bias, as well as the potential for incomplete medical records and variability in surgical techniques over time. Further prospective studies are warranted to validate the observed associations and optimize treatment strategies for appendicular mass.

## 5. Conclusions

This retrospective study of 288 patients undergoing early appendectomy for appendicular mass found a predominance of cases below 30 years of age and a male bias. The most common diagnosis was appendicular lump with abscess. Loco-regional peritoneal toileting was the preferred surgical approach, showing potential benefits such as shorter operation times and possibly lower rates of wound infections compared to generalized peritoneal toileting. Further research is needed to confirm these findings and optimize treatment strategies.



## Abbreviations

STATA Statistical Software for Data Science

## Author Contributions

**Jahangir Md Sarwar:** Conceptualization, Methodology, Project administration, Writing – original draft, Writing – review & editing

**Abul Kalam Md Shamsuddin:** Writing – original draft, Writing – review & editing

**Sirajam Munira:** Conceptualization, Data curation, Formal Analysis, Investigation, Methodology, Software, Supervision, Validation, Visualization, Writing – original draft, Writing – review & editing

## Conflicts of Interest

The authors declare no conflicts of interest.

## References

- [1] Senapathi PSP, Bhattacharya D, Ammori BJ. Early laparoscopic appendectomy for appendicular mass. *Surg Endosc Other Interv Tech.* 2002; 16:1783–5. <https://doi.org/10.1007/s00464-001-9232-1>
- [2] Ponsky TA, Kittle K, Eichelberger MR, Gilbert JC, Brody F, Newman KD. Hospital- and patient-level characteristics and the risk of appendiceal rupture and negative appendectomy in children. *JAMA.* 2004; 292:1977–82. <https://doi.org/10.1001/jama.292.16.1977>
- [3] Furuya T, Inoue M, Sugito K, Goto S, Kawashima H, Kaneda H, et al. Effectiveness of interval appendectomy after conservative treatment of pediatric ruptured appendicitis with abscess. *Indian J Surg.* 2015; 77:1041–4. <https://doi.org/10.1007/s12262-014-1121-7>
- [4] Church JT, Klein EJ, Carr BD, Bruch SW. Early appendectomy reduces costs in children with perforated appendicitis. *J Surg Res.* 2017; 220: 119–24. <https://doi.org/10.1016/j.jss.2017.07.001>
- [5] SK, Talukdar R, Singh NK. Assessment of the relevance of interval appendectomy in treatment of appendicular lump: a prospective study. *Int J Sci Study* 2016; 4: 162–6.
- [6] Ram KR, Chandana S, Koshti S. A study of outcome of non-operative versus operative management in 50 cases of appendicular lump. *Int Surg J* 2017; 4: 2233–7.
- [7] Kumar CD, Abhijit S, Arupjyoti B, et al. Laparoscopic appendectomy in appendicular lump. *International Journal of Pharmaceutical Science Invention* 2013; 2: 1–2.
- [8] Bailey H. The Ochsner-Sherren (Delayed) Treatment of acute appendicitis: Indications and technique. *Br Med J* 1930; 1(3603): 140-3.
- [9] Dhanasekharan N, Raj P, Ganeshram P, Venkatesan V. Does Ochsner-Sherren Regimen Still Hold True in the Management of Appendicular Mass? Ochsner-Sherren Rejimi Halen Apendiküler Kitle Tedavisinin Düzenlenmesinde Geçerli Midir? *Ulus Travma Acil Cerrahi Derg* 2010; 16(1): 43-6.
- [10] Russel RCG, William NS. Vermiform appendix. In: *Short practice of surgery*; 24th edition; (2) 2004. pp. 1203 e8.
- [11] Lai HW, Loong CC, chiu JH, Chau GY, Wu CW, Lui WY. Interval appendectomy after conservative treatment of an appendiceal mass. *World J Surg* 2006 Mar; 30:352e 7.
- [12] Okune G, Marek, Jaros law K. Management of appendiceal mass In Children and adults: our experience. *Internet J Surg* 2007; 9(2).
- [13] Deakin DE, Ahmed I. Interval appendectomy after resolution of adult inflammatory appendix masses is it necessary? *Surgeon* 2007; 5(1): 45e 50.
- [14] Kim JK, Ryoo S, Oh HK, et al. Management of appendicitis presenting with abscess or mass. *J Korean Soc Coloproctol* 2010; 26(6): 413-419.
- [15] Tannoury J, Abboud B. Treatment options of inflammatory appendiceal masses in adults. *World J Gastroenterol* 2013; 19(25): 3942-3950.
- [16] Patel BJ, Patel KH. A comparative study of appendicular lump management. *Int Surg J* 2015; 2(2): 235-238.
- [17] Gilkar IA, Mushtaq U, Peer JA, et al. Management of appendicular lump at tertiary care hospital. *J. Evid. Based Med. Healthc.* 2019; 6(3), 135-138. <https://doi.org/10.18410/jebmh/2019/27>
- [18] Rahman, M. A. M., Chowdhury, T. K., Chowdhury, M. Z. et al. Early appendectomy for appendicular mass: operative findings and outcome in 220 children—a developing country perspective. *Ann Pediatr Surg* 16, 39 (2020). <https://doi.org/10.1186/s43159-020-00051-x>
- [19] Bahram MA. Evaluation of early surgical management of complicated appendicitis by appendicular mass. *Int J Surg.* 2011; 9(1): 101-3. <https://doi.org/10.1016/j.ijsu.2010.10.006> Epub 2010 Oct 20. PMID: 20965290.
- [20] Garba ES, Ahmed A. Management of appendiceal mass. *Ann Afr Med* 2008; 7(4): 200-204.
- [21] Corfield L. Interval appendectomy after appendiceal mass or abscess in adults: what is “best practice”? *Surg Today* 2007; 37(1): 1-4.
- [22] Ali M, Jahan KI. Early appendectomy in appendicular mass: review of literature. *Journal of Surgical Science* 2016; 20(1): 3335.
- [23] Ali Khan S, Ali M, Seerat MI. Efficacy of early exploration in appendicular mass. *Pakistan Journal of Medical & Health Sciences* 2016; 10(3): 781-3. 674.
- [24] Arshad M, Aziz LA, Qasim M, Altaf K, Talpur H. Early appendectomy in appendicular mass—a Liaquat University Hospital experience. *J Ayub Med Coll Abbottabad* 2008; 20(1): 70-2.